

Original article:

Prevalence and Surgical Outcome of Inguinal Hernia in Children at Tertiary Care Hospital in India

Sarita Kanth¹, Pramod Kumar²

¹Associate Professor, Department of General Surgery, Kasturba Medical College, Manipal, Karnataka, India.

²Professor, Department of Plastic Surgery, Kasturba Medical College, Manipal, Karnataka, India.

Corresponding author: Dr. Pramod Kumar, Professor, Department of Plastic Surgery, Kasturba Medical College, Manipal, Karnataka, India. Email: pkplasticsurgerympl@yahoo.com

Date of submission: 24 March 2010, Date of acceptance: 28 May 2010

ABSTRACT

Introduction: Hernia is defined as a protrusion of an organ through an abdominal opening in the muscle wall of the cavity that surrounds it. It may be congenital or may result from the failure of certain structures to close after birth or may acquire later in life because of obesity, muscular weakness, surgery or illness.

Materials and Methods: Ultrasonography can be used routinely in the preoperative diagnosis of inguinal hernia in children. Laparoscopic inguinal hernia repair in pediatric patient is often considered controversial but as surgeon gains experience it has been proved to be feasible, safe and reliable technique. Physical examination of students was performed in presence of a parent in the same paediatric and children ward in supine and upright position with and without valsalva maneuver. Hernial sac was identified, dissected, the proximal part was transfixed at the level of internal ring with absorbable suture and excised, repair of weak floor with absorbable sutures done in some cases.

Results: 250 patients were examined for inguinal hernia, their age up to 12 years out of which 170 was male and 80 were female, in which inguinal hernia were detected in 20 students (8%) of which 14 cases (70%) were right-sided, 5 (25%) were left-sided, and 1 (5%) were bilateral. In this study inguinal hernia were detected in 16 (80%) male and 4 (20%) female. Two emergency patients shows superficial infection as a Post-operative complication remaining have no any post-operative complications.

Conclusion: Early detection and repair of inguinal hernia in pediatric patients is essential to decrease the potential morbidity and operative complications. Thus, regarding to relatively high prevalence rate of these abnormalities and their irreversible complications and low level of people knowledge, public and health staff education and screening systems for diagnosis and appropriate treatment of these abnormalities seem to be necessary. This needs an increase in population, pediatrician, parents, and surgeon awareness.

Keywords: Hernia, Inguinal Hernia, Protrusion, Obesity.

INTRODUCTION

Hernia is defined as a protrusion of an organ through an abdominal opening in the muscle wall of the cavity that surrounds it.¹ It may be congenital or may result from the failure of certain structures to close after birth or may acquire later in life because of obesity, muscular weakness, surgery or illness.² The common sites of herniation are the groin, umbilicus, linea alba, semilunar line of spiegelhel, diaphragm and surgical incisions.³ The inguinal canal is a passage through the lower abdominal wall. People have two inguinal canals one on each side of the lower abdomen. In males, the spermatic cords pass through the inguinal canals and connect to the testicles in the scrotum-the sac around the testicles. The spermatic cords contain blood vessels, nerves, and a duct, called the

spermatic duct, that carries sperm from the testicles to the penis. In females, the round ligaments, which support the uterus, pass through the inguinal canals.

Inguinal hernia, hydrocele and other inguino-scrotal abnormalities are the most common congenital disorders and its repair represents one of the most common operations performed in children.⁴ Abnormalities of external genitalia in male elementary students have a prevalence rate between 6.6 to 18.7%.⁴ The most common disorders of external genitalia include inguinal hernia, varicocele, undescended testis (UDT), hydrocele, hypospadias, epispadias, and micropenis.^{5,6} Prevalence of inguinal hernia is about 1-5% in general population.⁷ Approximately 3% to 5% of term infants may be born with an inguinal hernia. Preterm infants have a higher incidence (9% to 11%). Approximately 80% to 90% of inguinal hernias appear in boys. Male to female ratio of inguinal hernia varies from 4:1 in infants to 12-25:1 in adults.⁸ If strangulated, inguinal hernia may lead to loss of testis and life threatening situations.⁹

The presence of an inguinal hernia in a child is an indication for surgical repair.^{10,11} Pediatric inguinal hernia is a result of a congenital patent processus vaginalis (PPV) as a direct consequence of normal events in fetal development. Protrusion of PPV presents as a potential hernia and approximately 10% of these develop clinical hernia. In preterm infants, the incidence may be as high as 30%.¹² The right side is involved in 60% and the left in 30% of patients; bilateral hernias are seen in 10%.¹² About one third of children with Inguinal Hernia are younger than 6 months, and males are affected about six times more often than females¹², and even more often in premature baby.¹³ Approximately 40% of children with a clinical unilateral inguinal hernia display a patent processus vaginalis on the contra lateral side, half of these children subsequently develop an inguinal hernia. Ultrasonography can be used routinely in the preoperative diagnosis of inguinal hernia in children. PPV values higher than 4 mm, indicate hernia with a high accuracy rate.¹³ Laparoscopic inguinal hernia repair in pediatric patient is often considered controversial but as surgeon gains experience it has been proved to be feasible, safe and reliable technique. Pediatric patients with inguinal hernia can be good candidates for day care surgery. Recurrence, injury to the vas deferens, wound infection, and postoperative hydrocele are recognized complications associated with Inguinal Hernia repair but occur with a frequency of less than 1%. Most recurrences occur two years after the initial surgery.¹⁴

MATERIALS AND METHODS

A prospective study conducted in the pediatric patients admitted in paediatric and children ward of the hospital in surgery department. Physical examination of students was performed in presence of a parent in the same paediatric and children ward in supine and upright position with and without valsalva maneuver. A written consent was obtained from parents before examination.

Hernial sac was identified, dissected, the proximal part was transfixed at the level of internal ring with absorbable suture and excised, repair of weak floor with absorbable sutures done in some cases. The external oblique aponeurosis and the subcutaneous fatty tissue was then closed in two layers, skin was closed by sub cuticle method with absorbable suture vicryl 3-0 cutting needle. The content of the hernia sacs, associated conditions noted pre and per-operatively. There were some associated pathologies like hydrocele, undescended testis, phimosis, umbilical hernia excluded from study. Post operative transient scrotal swelling which was not mentioned because they are not seen in female patients. Post operative complications including scrotal swelling, superficial wound infection, deep collection, fever, and recurrence were recorded during the subsequent followup by 3 days, 1 week, 1 month, six month checking.

RESULTS

In this study, 250 patients were examined for inguinal hernia, their age up to 12 years out of which 170 was male and 80 were female, in which inguinal hernia were detected in 20 students (8%) of which 14 cases (70%) were right-sided, 5 (25%) were left-sided, and 1 (5%) were bilateral. In this study inguinal hernia were detected in 16 (80%) male and 4 (20%) female. Two emergency patients shows superficial infection as a Post operative complication remaining have no any post-operative complications.

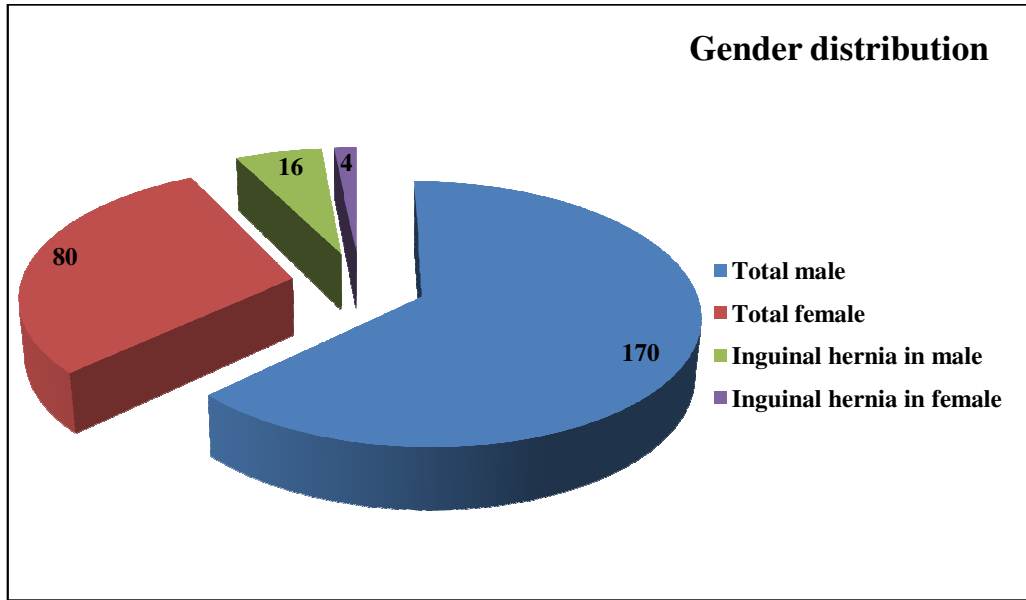


Figure 1: Gender distribution

Table 1: Relations between the sex of patients and sides of hernias.

Site of hernia	Male		Female		Total	
	Number	Percentage	Number	Percentage	Number	Percentage
Right side	10	50	3	15	13	65
Left side	4	20	1	10	05	30
Bilateral	2	10	0	00	02	10
Total	16	80	04	20	20	100

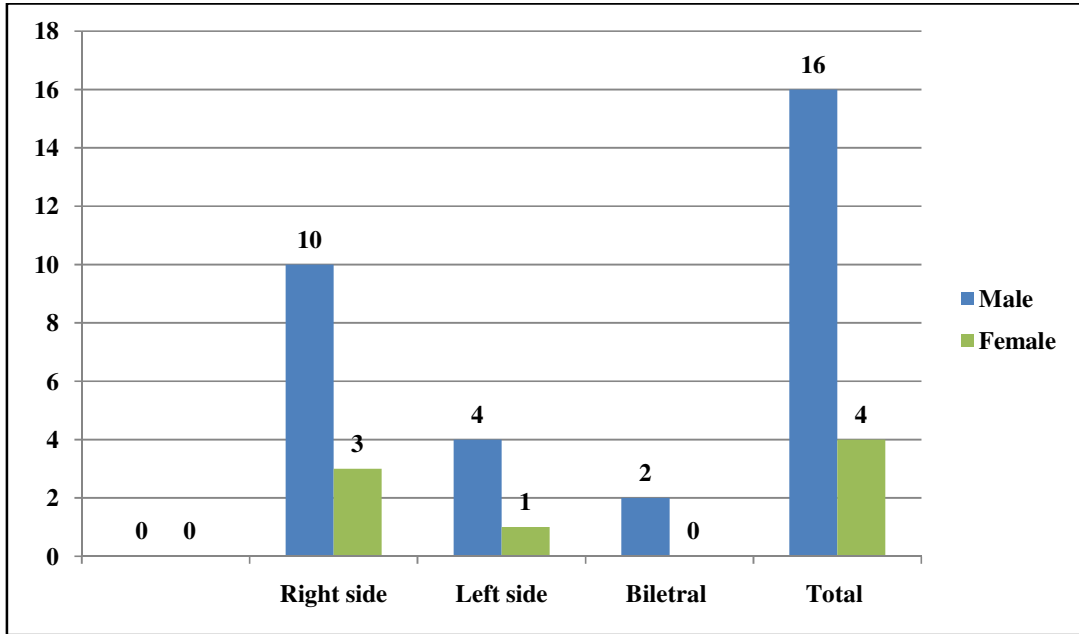


Figure 2: Relations between the sex of patients and sides of hernias.

DISCUSSION

The inguinal hernia is one of the most frequently performed surgical procedures in pediatric patients. An inguinal hernia does not resolved spontaneously and must be repaired because of high risk of strangulation or incarceration. Prevalence rate of inguinal hernia was 8% in this study. Female patients less reported hernia, which may explain on the social background of our people that wouldn't present their female earlier. In our study, out of 250 patients, the male to female ratio was approximately 4:1, which shows a decreased number of females in comparison to other studies.^{12,15} A total of 13 patients presented with right, 5 with left and 2 were having bilateral inguinal hernia, which represent a 65%,25% and 10% of cases respectively and these are comparable with the 60%, 30% and 10% respectively reported.^{12,16}The presence of an inguinal hernia in a child is an indication for surgical repair. Pediatric inguinal hernia is a result of a congenital patent processus vaginalis (PPV) as a direct consequence of normal events in fetal development. Ultrasonography can be used routinely in the preoperative diagnosis of inguinal hernia in children. Laparoscopic inguinal hernia repair in pediatric patient is often considered controversial but as surgeon gains experience it has been proved to be feasible, safe and reliable technique. Pediatric patients with inguinal hernia can be good candidates for day care surgery. Physical examination of students was performed in presence of a parent in the same paediatric and children ward in supine and upright position with and without valsalva maneuver. Hernial sac was identified, dissected, the proximal part was transfixed at the level of internal ring with absorbable suture and excised, repair of weak floor with absorbable sutures done in some cases. The external oblique aponeurosis and the subcutaneous fatty tissue was then closed in two layers, skin was closed by sub cuticle method with absorbable suture vicryl 3-0 cutting needle. The content of the hernia sacs, associated conditions noted pre and per-operatively. In this study inguinal hernia were detected in 16 (80%) male and 4 (20%) female. Two emergency patients shows superficial infection as a Post-operative complication remaining have no any post-operative complications. Early detection and repair of inguinal hernia in pediatric patients is essential to decrease the potential morbidity and operative

complications. Thus, regarding to relatively high prevalence rate of these abnormalities and their irreversible complications and low level of people knowledge, public and health staff education and screening systems for diagnosis and appropriate treatment of these abnormalities seem to be necessary. The rate of post-operative complications was 10%, this means that the numbers of complications are increased highly in the emergency cases, which necessitates the early management of inguinal hernia.

CONCLUSION

Early detection and repair of inguinal hernia in pediatric patients is essential to decrease the potential morbidity and operative complications. Thus, regarding to relatively high prevalence rate of these abnormalities and their irreversible complications and low level of people knowledge, public and health staff education and screening systems for diagnosis and appropriate treatment of these abnormalities seem to be necessary. This needs an increase in population, pediatrician, parents, and surgeon awareness.

REFERENCES

1. Sultan B., et al. "Frequency of external hernias in Ayub Teaching Hospital Abbottabad". *Journal of Ayub Medical College Abbottabad* 21.3 (2009): 57-58.
2. Glanze WD., et al. "Mosby Medical and Nursing Dictionary". The C. V. Mosby Company, Saint Louis. 2nd edition (1986): 528.
3. Schwartz SI., et al. "Principles of Surgery". B. I. Waverly Ltd. New Delhi, 7th edition (1999): 1585-1592.
4. Yegane RA, Kheyrollahi AR, Bashashati M, et al. The prevalence of penoscrotal abnormalities and inguinal hernia in elementary school boys in the west of Iran. *Int J Urol* 2005; 12(5): 479-483.
5. Ghazzel AM. Inguinal hernias and genital abnormalities in young Jordanian males. *East Mediterr Health J* 2006; 12(3-4): 483-88.
6. Diniz G, Barutcuoglu M, Unalp A, et al. Evaluation of the relationship between urogenital abnormalities and neuromuscular disorders. *East J Med* 2008; 13(1-2).
7. Lugo-Vicente H. Recurrent inguinal hernias. *Pediatric Surgery Update* 2003; 21(6): 27-33.
8. Tarlan S, Khayati B. [Evaluation of the necessity of bilateral inguinal exploration in unilateral inguinal hernia among preschool age group.] *Persian. J Qazvin Univ Med Sci* 2005; 9(3): 71-73.
9. Abbadi K, Smadi SA. Genital abnormalities and groin hernias in elementary-school children in Aqaba: An epidemiological study. *East Mediterr Health J* 2000; 6(2): 293-8.
10. Schwartz principle of surgery, 8th edition, F Charles Brunnicardi 38: pediatric surgery.
11. Bailey and Love's, Short practice of surgery, 25th edition, Norman S. Williams, Christopher J. K. Bulstrode and P. Roman O'connell 6: Principle of pediatric surgery 71-89.
12. Sabiston Textbook of Surgery 18th edition, The Biological Basis Of Modern Surgical Practice, Section XIII Specialities in General Surgery, Chapter 71 Pediatric Surgery, Abdominal wall.
13. Kervancioglu, M. M. Bayram, I. Ertaskin and A. Ozkur. Ultrasonographic evaluation of bilateral groins. In children with unilateral inguinal hernia. *Acta Radiologica* 2000;41:653.
14. Humberto Lugo- Vicente. Incarcerated inguinal hernias. *Pediatric Surgery Update* 2003;21:397-403.
15. Abdul Salam, Akhtar J, Abdul Aziz. Irreducible inguinal hernia in children. *Pak J Surg* 1998;14:34-6.
16. Rowe MI, Clatworthy HW Jr. The other side of the pediatric inguinal hernia. *SurgClin North Am* 1971;51:1371-6.